

# Morphometric analysis of chondromalacia patella and patella types

Emre Ögüt<sup>1</sup>, Ayşe Gül Kabakçı<sup>2</sup>, Hakan Saygılı<sup>3</sup>, Memduha Gülhal Bozkır<sup>2</sup>

<sup>1</sup>Department of Physical Therapy and Rehabilitation, Kozan State Hospital, Adana, Turkey

<sup>2</sup>Department of Anatomy, Faculty of Medicine, Çukurova University, Adana, Turkey

<sup>3</sup>Department of Orthopedics and Traumatology, Kozan State Hospital, Adana, Turkey

**Cite this article as:** Ögüt E, Kabakçı AG, Saygılı H, Bozkır MG. Morphometric analysis of chondromalacia patella and patella types. *J Med Palliat Care*. 2023;4(6):663-671.

Received: 18.10.2023

Accepted: 17.12.2023

Published: 31.12.2023

## ABSTRACT

**Aims:** The present study was conducted to determine patella types, chondromalacia patella finding in the Turkish society, and to evaluate the differences between gender and age groups to with Magnetic Resonance Imaging (MRI).

**Methods:** The study had a retrospective design, and included 256 people (122 females, 134 male) who were between the ages of 18 and 81 admitting to the Orthopedic Clinic of Kozan State Hospital with various complaints in knee joints and different preliminary diagnoses between January 2015 and December 2017. The evaluations made on MR images in the study. We evaluated in our study were patella types, chondromalacia classification and comparison according to age and gender.

**Results:** Patella types did not differ between the genders at significant levels; however, significant differences were detected between the genders in the chondromalacia patella ( $p=0.03$ ). Patella types were classified, and it was found that Type II Patella was the most common patella type, and Type IV was identified as the least common.

**Conclusion:** We believe that the data obtained in our study will be useful in understanding morphometry of patella in anatomy, radiology and orthopedics fields. Based on our findings, we concluded that the anatomical shape of the patella is an important anatomic parameter, which may reflect the development of defects in the patellofemoral region It is also clinically important in terms of identifying knee pathologies more clearly in the aging process, and revealing the differences between societies, and in many pathologies that involve patella.

**Keywords:** Chondromalacia patella, knee, morphometry, patella types

## INTRODUCTION

The knee joint, which plays major role in the stabilization of the lower extremity, is the largest and most complex joint in the body. The knee joint, which has a wide range of motion, is also subject to overloads. An important part of the knee joint is the patellofemoral joint. Patella, which is an integral component of the extensor mechanism of the knee joint, helps to feed the patellofemoral joint cartilage of the femur by protecting the knee joint against direct impacts with its placement in the anterior part of the knee joint.<sup>1</sup> Also, the anatomical features of the patella and the femur and their compatibility with each other are very important in performing the flexion and extension movements of the knee. If the leverage of patella is increased, the effectiveness of the musculus quadriceps femoris is also increased. For this reason, patella joint movement width increases the extension moment arm. If abnormalities develop in the position of patella, problems such as chondromalacia patella, recurrent subluxations, and dislocation of patella develop in patellofemoral joint function.<sup>2</sup> Anatomical disorders in the patella and femur and the deterioration

of the harmony between these two bones may cause uneven distribution of the load on the patellofemoral joint, cartilage lesions and knee pain in the joint.<sup>3</sup> Knee pain is the second most prevailing disorder of knee and patellofemoral pain being considered one of the most common forms of knee pain, with incidence ranging between 15 and 45%. Patellofemoral pain is described as nontraumatic diffuse anterior knee pain during load bearing activities of the joint such as squatting, running, climbing, and descending stairs. Chondromalacia patella is an important cause of patellofemoral knee pain. Chondromalacia patella, also known as runner's knee, typically occurs in young patients, which is characterized by anterior knee pain that is associated with visible changes in patellar cartilage.<sup>4</sup> Patella type is considered to be an important factor in the etiology of chondromalacia patella. Although there were very few studies investigating the relations between chondromalacia patella and patella types, which is defined as the softening and ulceration of the patella back cartilage, which accompanies knee pain, no

**Corresponding Author:** Ayşe Gül KABAKCI, aysegulll-88@hotmail.com



This work is licensed under a Creative Commons Attribution 4.0 International License.

studies were detected in the literature investigating the distribution of these studies according to age groups. Although studies were detected on the distribution of patella types in our population, no studies were detected patella types in different age ranges.<sup>5</sup> Therefore, patella types and chondromalacia patella parameters were included in our study and their correlation with each other was examined. Wiberg et al.<sup>6</sup> classified patella types into 3 types, and Baumgartl et al.<sup>7</sup> divided them into 4 types. It was reported that medial and lateral facets are equal in Type I patella, medial facet remains smaller in Type II than the lateral, medial facet is small and close to convex and vertical in Type III, and there is no “middle corner” in medial facet, and the appearance is similar to a “Jockey hat” in Type IV.<sup>8,9</sup> Computed Tomography (CT) and Direct Graphic are used in pathologies regarding the knee joint, these methods do not provide as much detailed information as Magnetic Resonance Imaging (MRI).<sup>10</sup> Therefore, in our study, measurements were made on MRI images.

We thought that such a study could give an idea about the morphology of the patella and chondromalacia patella which are common in our population. So, our purpose was to determine the distribution of patella types in our population in which knee pathologies are most common between the ages of 18-81, the distribution of patella types in different age groups and in 7 different age ranges in both genders, patella types, and to determine the relations between them. Furthermore, this study will have significant clinical impact on the production of specific prostheses belonging to our population with similar anthropological patella shape.

## METHODS

The study was carried out with the permission of Çukurova University Non-interventional Clinical Researches Ethics Committee (Date: 02.06.2017, Decision No: 38). All procedures were carried out in accordance with the ethical rules and the principles of the Declaration of Helsinki.

### Patient Selection and Study Procedure

Retrospective MRI analysis was performed on patients who were hospitalized between January 2015 and December 2017. Our study included 256 people (122 women, 134 men) between the ages of 18 and 81, who applied to Kozan State Hospital between January 2015 and December 2017 with various complaints in the knee joint and were referred from clinics to the Radiodiagnostic Department for MRI examination with different preliminary diagnoses. Criteria for participating in the study;

- (1) Not having had any surgery on the lower extremity
- (2) No history of fractures of the lower extremities or column vertebrae and no neurological disorder
- (3) Not having real short legs
- (4) Not having congenital hip dislocation
- (5) Not having a benign or malignant mass in the knee joint
- (6) Not having arthritis and rheumatological findings in the knee joint
- (7) MRI images appear clear
- (8) Having consented to the use of MRI images

Our study design is to analyze the distribution of knee MRIs with and without chondromalacia according to age, gender and patella types. In addition, this study also includes the analysis of chondromalacia degrees of images with chondromalacia according to age, gender and patella types. This study is a retrospective study and not an experimental study on participants. It involves the anonymized use of MRI images on a voluntary basis. For this reason, anonymous analysis and images that do not contain personal information were used. Voluntary consent forms were obtained from the people whose MRI images we would use, and only the gender and age information of the patients were recorded.

### Magnetic Resonance Imaging And Measurements

Magnetic resonance imaging (MRI) is a radiation-free imaging technique that can be used to examine all soft tissues in the body. After the nervous system, the second most common area of use is the musculoskeletal system, especially the knee joint. In MRI, images can be obtained in many planes without moving the patient. MRI is a diagnostic method with high accuracy that can be routinely chosen for imaging articular cartilage. If 3D SPGR and FSE PD-weighted sequences are used with fat suppression technique, it will be possible to obtain valuable information about cartilage pathologies. In our study, the MRI examination of 256 patients was performed with Tesla MRI Device. In all cases, the images were obtained as T1-A SE in coronal plain, PD FSE in axial plain, and PD FSE in sagittal plan. MRI parameters were obtained in PD in sagittal plain (FSE:3800/19), in axial plain (FSE:3000/19), and coronal plain (FSE:2800/8).

All images included in this study consist of axial patella radiographs. Patella morphology was evaluated according to the Wiberg classification by two authors (E.Ö. and H.S.). Intraobserver comparisons have been made. Type 1, patellar tilt angle and patellar thickness/width were evaluated from the axial view of the patella; Type 2 was interpreted as lateral patellar displacement measured in the axial view of the patella; Type 3 was evaluated as the patellar compliance angle and patellar facet angle measured in the axial view of the patella; Type 4 was evaluated by interpreting the patellar height measured on the lateral of the knee.

The evaluations made on MR images in the study are as follows;

**Patella types:** The classification was made according to Wiberg and Baumgartl (1964), and patella was divided into 4 types (Figure 1).<sup>6,7</sup>

**Type I:** Medial - lateral facet shows equal and slightly concave appearance.

**Type II:** Medial facet is smaller, straighter, and convex compared to lateral.

**Type III:** Medial facet is small, convex, and close to the vertical.

**Type IV:** There is no medial facet and middle corner.

**Patellar chondromalacia classification:** The classification was made according to Outerbridge (1964) (Figure 2).<sup>11</sup> The classification was made according to Outerbridge (1964).<sup>11</sup> This classification is used as a simple, easy-to-use and reproducible grading system of articular

cartilage lesions. Chondromalacia classification was made based on MRI images.

Chondromalacia was divided into 4 grades;

**Grade 1:** Softening and swelling.

**Grade 2:** Fragmentation and fissuring (<0.5 cm).

**Grade 3:** Fragmentation and fissuring (>0.5 cm).

**Grade 4:** Cartilage erosion in subchondral bone.

**Age Decades:** The analyzed images were divided into 7 groups according to age ranges;

**Group I (1<sup>st</sup> decade):** 18-20 years,

**Group II (2<sup>nd</sup> decade):** 21-30 years,

**Group III (3<sup>rd</sup> decade):** 31-40 years,

**Group IV (4<sup>th</sup> decade):** 41-50 years,

**Group V (5<sup>th</sup> decade):** 51-60 years,

**Group VI (6<sup>th</sup> decade):** 61-70 years

**Group VII (7<sup>th</sup> decade):** 71 and over years.

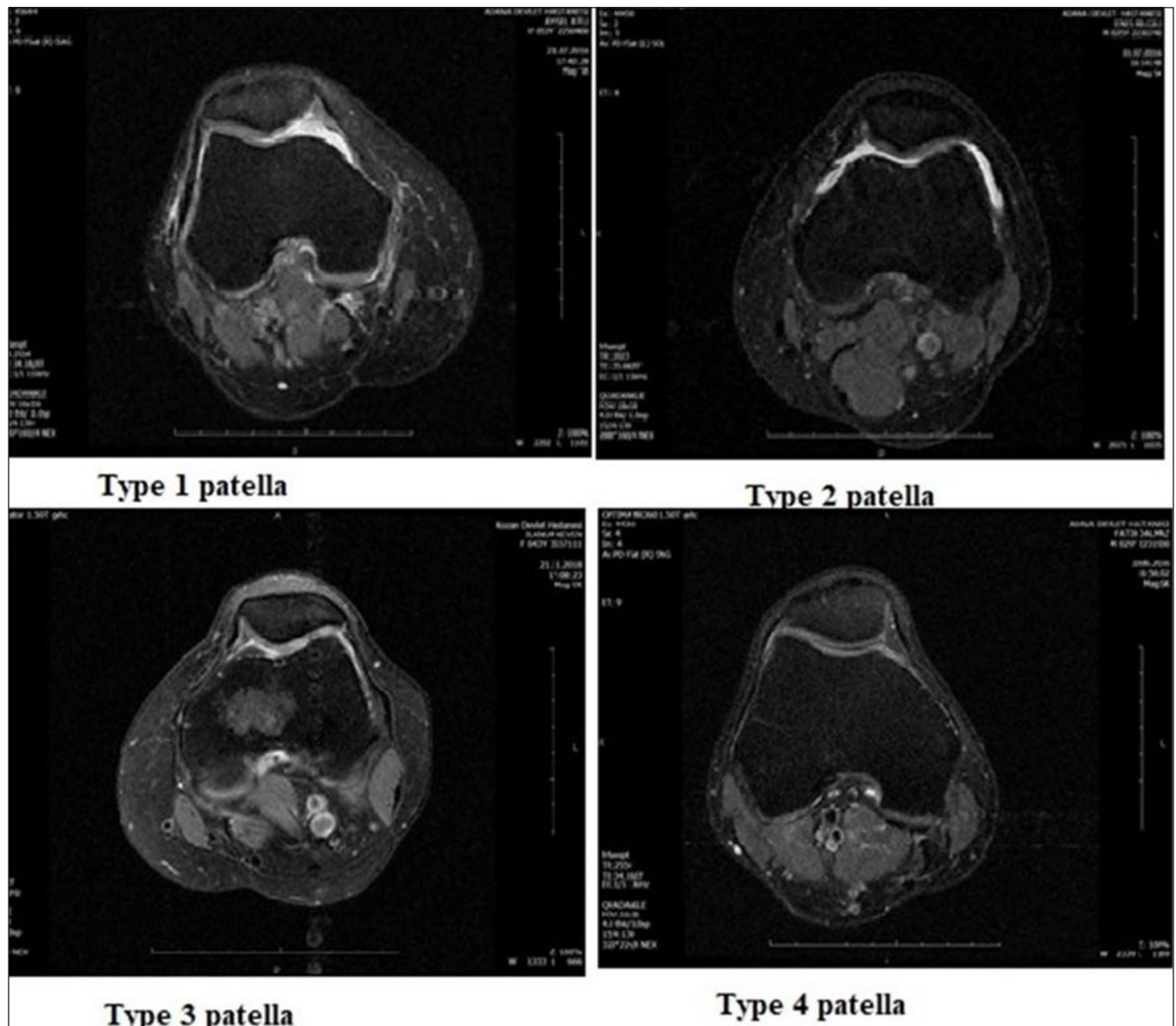


Figure 1. Patella types

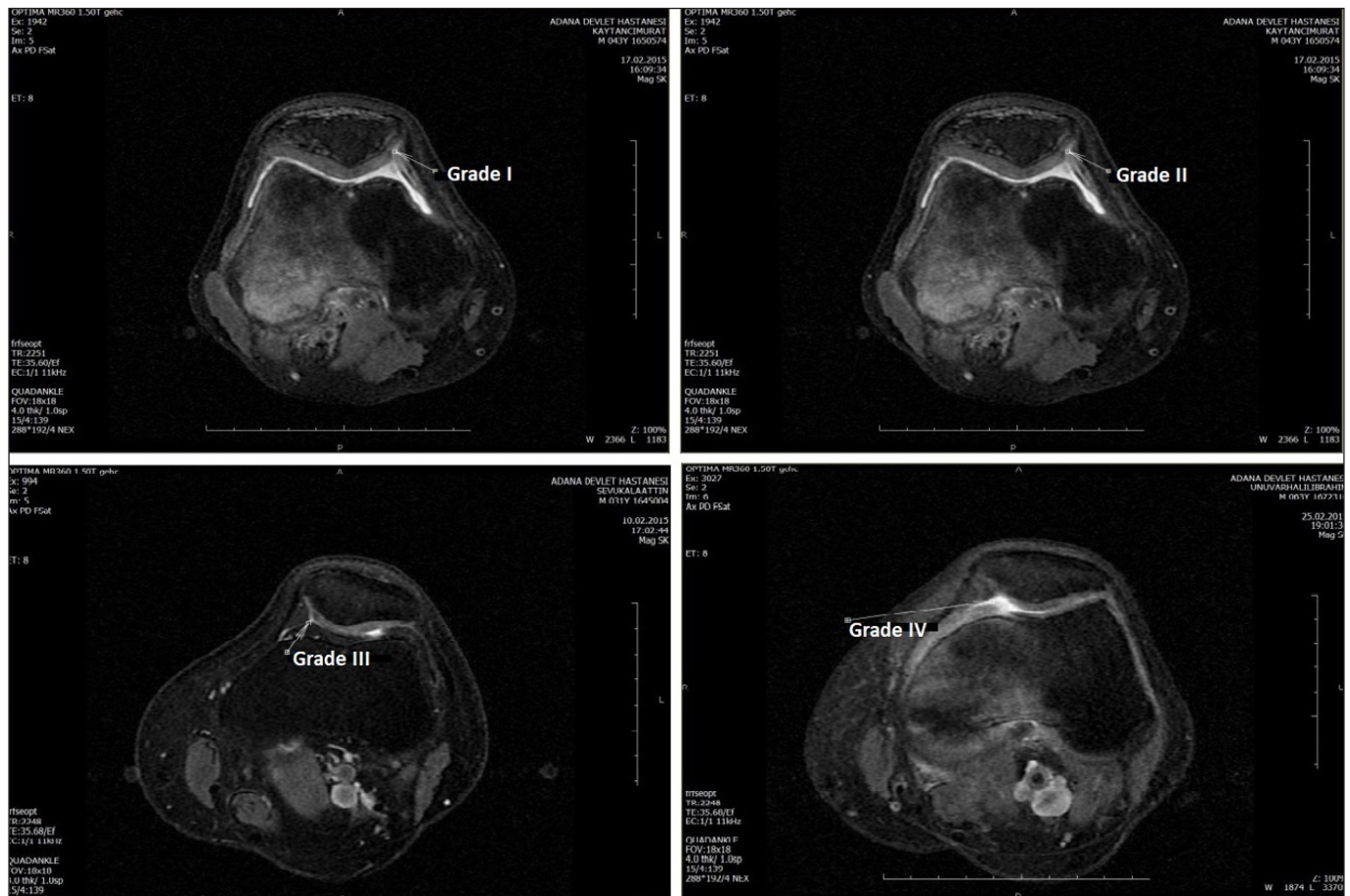


Figure 2. Grades of chondromalacia

### Statistical Analysis

“Statistical Package for Social Sciences for Windows 21” (SPSS 21 Inc.) Program was used for the statistical analyses of the data that were obtained in the study. When the study data were evaluated, mean values, standard deviation, minimum (min.)-maximum (max.) values, and % from descriptive statistical methods were used. According to whether the data showed normal distribution, which test method should be used was decided according to the result of the Kolmogorov-Smirnov Normality Test. ANOVA One-Way Test was used in the analysis of quantitative data since the data were distributed normally. Analysis of the qualitative data was made by using the Chi-Square Test. Pearson Correlation Test was used to examine the magnitude, direction, and significance of the relations between the two variables. The results were evaluated at 95% Confidence Interval, and the significance was taken as  $p < 0.05$ .

### RESULTS

In the present study, the MRI results of 256 healthy people, including 122 female and 134 male who were aged between 18 and 81 were evaluated. While there

was no significant difference ( $p=0.200$ ) between the genders in the distribution of patella types, there was a significant difference ( $p=0.003$ ) between the genders in the degree of chondromalacia (Table 1). In addition, while there was no significant difference ( $p=0.583$ ) between patella types in people younger than 45 years old and over 45 years old, we found a significant difference ( $p < 0.001$ ) between the two groups in terms of chondromalacia grade (Table 2). Moreover, Grade 4 chondromalacia patella was not detected in individuals with Type I patella in both genders. Grade 4 chondromalacia patella was not detected in individuals with Type II patella in both male and female. Male with Type III patella did not have Grade 4 chondromalacia patella, but female with Type III patella had Grade 3 chondromalacia patella. Grade 2 chondromalacia patella was detected only in 2 males with Type IV patella. Type IV patella was not detected in female (Table 3). When the distribution of patella types was examined according to the age decades, Type I patella was detected mostly in Group V, Type II in Group IV, Type III in Group IV, and Type IV patella in Group II and Group III. Also, when the types of chondromalacia were evaluated, significant differences were detected between age groups ( $p < 0.001$ ) (Table 4).

**Table 1.** The distribution of patella types and chondromalacia patella classification morphometric measurements according to gender

Measurements	Females (n=122) n(%)	Males (n=134) n(%)	P
Patella Types	Type I=26 (21.3%) Type II=78 (63.9%) Type III=18 (14.8%) Type IV=0 (0.0%)	Type I=38 (28.4%) Type II=71 (53.0%) Type III=23 (17.2%) Type IV=2 (1.5%)	0.200
Chondromalacia patella classification	No chondromalacia patella =14 (11.5%) Grade 1=57 (46.7%) Grade 2=24 (19.7%) Grade 3=25 (20.5%) Grade 4=2 (1.6%)	No chondromalacia patella =31 (23.1%) Grade 1=50 (37.3%) Grade 2=40 (29.9%) Grade 3=13 (9.7%) Grade 4=0 (0.0%)	0.003

**Table 2.** The results of patella types and chondromalacia patella classification according to age groups

Measurements	45 years and younger (n=138) n (%)	45 Years and over (118) n (%)	P
Patella Types	Type I=35 (25.4%) Type II=78 (56.5%) Type III=23 (16.7%) Type IV=2 (1.4%)	Type I=29 (24.6%) Type II=71 (60.2%) Type III=18 (15.3%) Type IV=0 (0.0%)	0.583
Chondromalacia patella classification	No chondromalacia patella=40 (29%) Grade 1=58 (42%) Grade 2=31 (22.5%) Grade 3=9 (6.5%) Grade 4=0	No chondromalacia patella=5 (4.2%) Grade 1=49 (41.5%) Grade 2=33 (28%) Grade 3=29 (24.6%) Grade 4=2 (1.7%)	<0.001

**Table 3.** The relation between patella types and the genders of chondromalacia distributions

Patella types	Gender n (%)	Grade 1 n (%)	Grade 2 n (%)	Grade 3 n (%)	Grade 4 n (%)	Total n (%)
Type 1	Male 10 (26.3%)	18 (47.4%)	7 (18.4%)	3 (7.9%)	0 (0.0%)	38 (100%)
	Female 3 (11.5%)	9 (34.6%)	7 (26.9%)	7 (26.9%)	0 (0.0%)	26 (100%)
	Total 13 (20.3%)	27 (42.2%)	14 (21.9%)	10 (15.6%)	0 (0.0%)	64 (100%)
Type 2	Male 17 (23.9%)	26 (36.6%)	22 (30.99%)	6 (8.45%)	0 (0.0%)	71 (100%)
	Female 7 (9.0%)	39 (50.0%)	14 (17.9%)	18 (23.1%)	0 (0%)	78 (100%)
	Total 24 (16.1%)	65 (43.6%)	36 (24.2%)	24 (16.1%)	0 (0.0%)	149 (100%)
Type 3	Male 4 (17.39%)	6 (26.09%)	9 (39.13%)	4 (17.39%)	0 (0.0%)	23 (100%)
	Female 4 (22.2%)	9 (50.0%)	3 (16.7%)	0 (0.0%)	2 (11.1%)	18 (100%)
	Total 8 (19.5%)	15 (36.6%)	12 (29.3%)	4 (9.8%)	2 (4.9%)	41 (100%)
Type 4	Male 2 (100%)	0 (0.0%)	2 (100%)	0 (0.0%)	0 (0.0%)	2 (100%)
	Female 0 (0.0%)	0 (0.0%)	0 (0.0%)	0 (0.0%)	0 (0.0%)	0 (0.0%)
	Total 0 (0.0%)	0 (0.0%)	2 (100%)	0 (0.0%)	0 (0.0%)	2 (100%)

**Table 4.** The distribution of patella types and chondromalacia patella classification according to different age groups

Groups	Group I n=25	Group II n=34	Group III n=53	Group IV n=79	Group V n=47	Group VI n=16	Group VII n=2
<b>Patella Types</b>							
Type 1	6	10	13	14	15	5	1
Type II	13	16	32	55	24	8	1
Type III	6	7	7	10	8	3	0
Type IV	0	1	1	0	0	0	0
p=0.743							
<b>Chondromalacia Classification</b>							
No chondromalacia patella	13	15	9	6	1	1	0
Grade 1	7	12	30	37	18	3	0
Grade 2	4	6	9	23	13	8	1
Grade 3	1	1	5	13	13	4	1
Grade 4	0	0	0	0	2	0	0
p<0.001							

## DISCUSSION

One of the most common problems in orthopedics is patellofemoral joint diseases. Patellofemoral pain is defined as pain around the patella due to activities (squats, running, climbing, etc.) that load the patellofemoral joint without pathological changes. This is one of the most common forms of knee and lower extremity pain, with an annual prevalence of 23% in the general population and 29% in adolescents.<sup>12</sup> The negative effects of patellofemoral pain are high individuals with patellofemoral pain often report a lower quality of life. Patellofemoral malalignment creates an inappropriate biomechanical environment, causing instability due to ligament insufficiency, and chondropathy/arthrosis and/or anterior knee pain through strain and/or damage to soft tissues and cartilage. For this reason, it is one of the most emphasized problems. Alignment corrective interventions are among the surgical methods used to solve this biomechanical problem. When patellofemoral joint diseases were examined in the literature, many researchers focused on the patellar aspect of the joint and on the changes in patellar morphology. For this reason, having accurate anatomical knowledge on joint anatomy and functioning, and understanding different anomalies that may cause clinical manifestations accompanying joint damage are extremely important in diagnosis and treatment. Besides creating a shield to protect the distal femur, the patella also contributes to the cosmetic appearance of the knee. Moreover, there is a large variance in physical size and articular surface shape of the patella, and its morphology has an influence on patella kinematics.<sup>13</sup> Wiberg classified patella types into 3 by considering patella medial and lateral facet lengths.<sup>6</sup> Then, the fourth type of patella was identified by Baumgartle.<sup>7</sup> According to this classification, when patella is classified, it was considered that the distinctions between Type II and Type III, and Type I and Type II were difficult; therefore, there might be differences according to the researchers who made the typing, which might then cause differences in the results of the first studies.<sup>14,15</sup> There are studies in the literature investigating the incidence of patella types both in Turkish society and in other societies. When studies conducted in Turkish society were evaluated, it was seen that patella Type II was most commonly detected in the study conducted by Atbasi et al.<sup>15</sup> 2013. In a study conducted by Kaplan et al.<sup>16</sup> which examined the patella type distribution in Sakarya, it was reported that Type II patella were detected by 70%. According to another study found Type I, II, and III were 24%, 70%, and 6%, respectively. They didn't found type IV.<sup>17</sup> In our study, the most Type II patella was found which supports the literature.

In a study conducted with 302 people (164 female, 138 male) by using MRI, they evaluated that there were 15 Type I patellas (9%), 114 Type II patellas (69.5%), and 35 Type III patellas (21.3%) and Type IV patellas was not detected in female; in male, it was reported that there were 26 Type I patellas (18.8%), 93 Type II patellas (67.3%), 18 Type III patellas (13%), 1 Type IV patella (0.7%).<sup>9</sup> When male and female were evaluated together, it was found that Type I patella was at a rate of 13%, Type II patella 68%, Type III patella 17.5%, and Type IV patella 0.3%. In their study, Arslan et al.<sup>8</sup> evaluated patella types and the frequency of chondromalacia in 1804 patients (806 females, 998 males), and reported that there were 159 Type I patellas (19.7%), 299 Type II patellas (37.1%), 342 Type III patellas (42.4%), and 6 Type IV patellas (0.7%) in female. They also reported that there were 199 Type I patellas (19.9%), 463 Type II patellas (46.4%), 321 Type III patellas (32.2%), 15 Type IV patellas (1.5%) in male. It was also found that Type II patella was most common in male, and Type III patella in female; and when calculated regardless of gender, Type II patella was most common. When other populations were examined, in the study conducted by the first studies that, Type II patella was detected in 57%, Type I patella in 24%, and Type III patella in 19%.<sup>8,14</sup> Gudas et al.<sup>18</sup> found that patients with a Type III patella shape (mean of  $3.10 \pm 0.99$ ) were less physically active compared to Type II (mean of  $4.48 \pm 0.88$ ;  $p=0.004$ ) and Type I (mean of  $4.55 \pm 0.72$ ;  $p=0.002$ ). The patients with Type I and II patella shapes had a similar level of physical activity ( $p=0.51$ ) in their study. In another study, Rahman et al.<sup>19</sup> were measured 82 (52.6%) right knees, while were 54 (47.4%) left knees. Based on patella types, 94 (60.3%) patellae were Type I patella, 53 (34.0%) were Type II, and 9 (5.7%) were Type III patella in 156 Asian female patients.

In the present study, Type I patella was detected in 26 female (21.3%) (122 female 134 male), Type II patella in 78 female (63.9%), Type III patella in 18 female (14.8%), and Type IV patella was not seen in female. Type I patella was detected in 38 male (28.4%), Type II patella in 71 male (53.0%), Type III patella in 23 male (17.2%), and Type IV patella in 2 male (1.5%). In the present study, male and female (63.9%) and male (53.0%) had mostly Type II patella. Wiberg and Outerbridge believed in an association between Type II patella and chondromalacia patella, while many researchers rejected the hypothesis of an association between patella types in the etiology of chondromalacia patella.<sup>6,11</sup> However, in our study, the most Type II patella was found in both genders, which supports the Wiberg and Outerbridge hypothesis.

Moreover, it was reported in the study that was conducted by Hayırlioğlu et al.<sup>9</sup> that 8 chondromalacia were detected in Type I patella, 31 chondromalacia in

Type II patella, 8 chondromalacia in Type III patella, and no chondromalacia was detected in Type IV. It was also observed that chondromalacia was most commonly detected in Type II patella in male and female. Patella problems arise in the knee when it is under heavy load. The cartilage under the patella begins to be damaged. This damage is called chondromalacia patella. Therefore, we can say that Type II patella is more inclined to chondromalacia. In Hayırlıoğlu et al.<sup>9</sup> study, a total of 129 knees that were diagnosed with chondromalacia patella were evaluated in terms of chondromalacia degrees, and it was found that Grade 1 chondromalacia was in 22 knees, Grade 2 chondromalacia in 30 knees, Grade 3 chondromalacia in 28 knees, and Grade 4 chondromalacia in 49 knees. It was emphasized that the frequency of high-grade (Grade 3 and 4) chondromalacia was higher at 59%. Also, in their study, Arslan et al.<sup>8</sup> reported incidence of chondromalacia patella that there was Type I patella in female at a rate of 45.9% (73 people), Type II patella in 42.1% (126 people), Type III patella in 50.6% (173 people), and Type IV patella in 50.0% (3 persons); and in male, there was Type I patella in 23.1% (46 people), Type II patella in 22.4% (104 people), Type III patella in 27.4% (88 people), 13.3% (2 persons) in Type IV patella, respectively. In the present study, only 2 male in Type IV patella had Grade 2 chondromalacia patella, 51 chondromalacia in Type I patella, 125 chondromalacia in Type II patella, 36 chondromalacia in Type III patella. Type IV patella was not detected in female. When 214 knees that had chondromalacia patella were evaluated in terms of chondromalacia degree, Grade 1 chondromalacia was detected in 107 knees, Grade 2 was detected chondromalacia in 64 knees, Grade 3 chondromalacia was detected in 38 knees, and Grade 4 was detected chondromalacia in 2 knees. A total of 10 people with Type I patella did not have chondromalacia patella in male, but 28 had chondromalacia patella. Three people did not have chondromalacia patella in female with Type I patella, but 23 had chondromalacia patella. Grade 4 chondromalacia patella wasn't found in individuals with Type I patella in both genders. There was no chondromalacia patella in 17 people in male in Type II patella, but chondromalacia patella was detected in 54 people. A total of 7 people did not have chondromalacia patella in female with Type II patella, but 71 had chondromalacia patella. Grade 4 chondromalacia patella wasn't detected in individuals with Type II patella in both genders. Although there was no chondromalacia patella in 4 males with Type III patella, 19 had chondromalacia patella. In female with Type III patella, 4 females did not have chondromalacia patella, but chondromalacia patella was detected in 14 people. Male with Type III patella did not have Grade 4 chondromalacia patella, but female with Type III patella

did not have Grade 3 chondromalacia patella. Grade 2 chondromalacia patella was detected only in 2 males with Type IV patella. Type IV patella was not detected in female. In the study conducted by Demir et al.<sup>20</sup> on one hundred and twenty-five patients with 3-4 degree chondromalacia patellae and an average age of  $48.8 \pm 8.7$ , they stated that 62.4% of the patients were women and 55.2% were on the right side. Additionally, they did not find any significance between genders between those with and without chondromalacia.

There are studies in the literature trying to explain the associations of patella types with anterior knee pain, meniscopathy, and chondromalacia patella. In the study conducted on patella types, it was considered that patella types were not associated with chondromalacia patella, but could cause anterior knee pain. Wiberg and Outerbridge also considered that there might be an association between chondromalacia patella and Type III patella, but they could not prove it. In our study, no associations were detected between patella types and chondromalacia.<sup>6,9,15,16</sup> Another study conducted also showed a correlation between the retinaculum lateral width of the ligamentum patella and Type III patella.<sup>21</sup> Also, the correlations between articular cartilage defects and the shape of the patella would be extremely important for understanding the mechanisms of articular cartilage defects in the patellofemoral region. Gudas et al.<sup>18</sup> study suggests that a significantly higher number of articular cartilage defects cases in the patellofemoral region were documented in patients having a patella with a Type III shape. In their study, they observed that patients with Type III shape of the patella have lower levels of physical activity compared to patients with Type I and II shapes. Furthermore, Wiberg showed that the shape of the patella was correlated with anterior knee pain and that the Type III anatomical configuration of the patella leads to defects, while the type I could be emphasized as ideal.<sup>6</sup> In a study, patella subluxations and similar pathologies were excluded from Sirik&Uludag study. Medio-lateral ratio was used in their study to make the classification of patella types more objectively, and measurements were made by one single researcher like our study. Although high grade (Grade 3 and Grade 4) chondromalacia patella was found to be 18% in their study.<sup>22</sup> Like recurrent dislocation, recurrent subluxation is the second-decade disease in the age group. Patellar dislocation, either as a direct traumatic event in a patient with normal patellar alignment, or with a previous underlying patellofemoral malalignment; may occur, especially in patients with advanced subluxation. Moreover, Fithian et al.<sup>23</sup> investigated prospectively patients who presented with acute patellar dislocation between 2-5 years in their study. They divided the patients into two groups as acute and recurrent patellar dislocation. As a result, they found

that female between the ages of 10-17 had the highest risk for acute and recurrent dislocations. Besides, Dai et al.<sup>24</sup> showed that type III patella were associated with patellofemoral osteoarthritis in 150 knees. In our study, type III patella was more common in male and was seen in the 41-50 age group. It can be said that males with Type III patella and chondromalacia are more inclined to defects in the patellofemoral region.

In addition, the skin incision to be chosen for osteotomy in knee arthroscopy may vary. The patella is an important landmark in determining the type of incision. Patella type is also important for determining this incision type. Thus, the correct skin incision to be selected for osteotomy provides an advantage in terms of both wound problems and the fact that the heads of the screws to be placed are not directly under the skin. We also think that with this study, we will contribute to the selection of the right incision type by determining the patella types according to age.

### Study Limitations

We recognize several limitations in this study. Firstly, our study only analyzed the imaging findings, which need to be studied in combination with the patient's symptoms in the future. Secondly, the physical activity status of the individuals should also be evaluated in terms of patella type and chondromalacia distribution. Thirdly, we think that if more knees are evaluated, determination of the standard of patella types may be more effective. Also, since our study was retrospective, intraobserver and interobserver comparisons have not been made. In addition, we could not obtain demographic data other than age and gender, which was a limitation of our study. The study can be conducted multicenterly with more patients and analyzed with demographic data other than age and gender. Moreover, another limitation of our study, are that the patients included in the study were diagnosed with chondromalacia by MRI without arthroscopy.

### CONCLUSION

Our study involved healthy individuals who were between the ages of 18 and 81. When chondromalacia patella types were evaluated, significant differences were detected between age groups ( $p < 0.001$ ). Patella types did not differ at significant levels between the genders, and chondromalacia patella showed significant differences between the genders. Also, Type II patella was most commonly detected in male and female. In the comparisons made regardless of gender, Type II patella was detected to be the most common. When the distribution of chondromalacia types was evaluated regardless of gender according to patella types, it was

found to be  $p = 0.091$ , and  $p = 0.274$  for female, and  $p = 0.10$  for male. In our study, when the distribution of chondromalacia patella was evaluated regardless of gender, chondromalacia patella was most commonly detected in individuals with Type II patella. A few studies were detected in the literature examining patella types in different age decades. For this reason, in the light of the available data, we believe that the findings of our study will contribute to the literature in understanding patella morphometry in the field of anatomy, radiology, and orthopedics in terms of determining knee pathologies more clearly in the aging process.

### ETHICAL DECLARATIONS

**Ethics Committee Approval:** The study was carried out with the permission of Çukurova University Non-interventional Clinical Researches Ethics Committee (Date: 02.06.2017, Decision No: 38).

**Informed Consent:** Because the study was designed retrospectively, no written informed consent form was obtained from patients.

**Referee Evaluation Process:** Externally peer-reviewed.

**Conflict of Interest Statement:** The authors have no conflicts of interest to declare.

**Financial Disclosure:** The authors declared that this study has received no financial support.

**Author Contributions:** All of the authors declare that they have all participated in the design, execution, and analysis of the paper, and that they have approved the final version.

### REFERENCES

1. Simonaitytė R, Rutkauskas S, Čekanauskas E, et al. First-time acute lateral patellar dislocation in children and adolescents: what about unaffected knee patellofemoral joint anatomic abnormalities? *Medicina*. 2021;57(3):206.
2. Yu Z, Yao J, Wang X, et al. Research methods and progress of patellofemoral joint kinematics: a review. *J Healthc Eng*. 2019;9:159267. doi:10.1155/2019/9159267
3. Yang B, Tan H, Yang L, et al. Correlating anatomy and congruence of the patellofemoral joint with cartilage lesions. *Orthopedics*. 2019;32(1):20.
4. Zheng W, Li H, Hu K, et al. Chondromalacia patellae: current options and emerging cell therapies. *Stem Cell Res Ther*. 2021;12(1):412. doi:10.1186/s13287-021-02478-4
5. Aktaş B, Komut E, Kültür T, et al. Patellar tendon yüksekliklerinin (patella alta ve patella baja) patella kondromalazisi ile ilişkisi. *KÜ Tıp Fak Derg*. 2015;17(2):1-8.
6. Cao L, Sun K, Yang H, et al. Influence of patellar morphology classified by Wiberg classification on knee joint function and patellofemoral tracking after total knee arthroplasty without patellar resurfacing. *J Arthroplasty*. 2021;36(9):3148-3153.
7. Dursun M, Ozsahin M, Altun G. Prevalence of chondromalacia patella according to patella type and patellofemoral geometry: a retrospective study. *Sao Paulo Med J*. 2022;140(6):755-761. doi:10.1590/1516-3180.2021.0206.R2.10012022



8. Arslan E, Acar T, Adıbelli H. Patellar chondromalacia in Turkish population: its prevalence and relationship with patella types. *J Tepecik Edu Res Hosp*. 2018;28(2):83-88.
9. Hayirlioglu A, Doganay H, Yilmabasar MG, et al. The evaluation of the association between patella types and chondromalacia patella by magnetic resonance imaging. *Int J Diagnostic Imaging*. 2015;2(2):21-28.
10. Yao I, Gentili A, Thomas A. Incidental magnetizasyon transfer contrast in fast spin- echoimaging of cartilage. *J Magn Reson Imaging*. 1996;6(1):180-184.
11. Slattery C, Kweon CY. Classifications in brief: outerbridge classification of chondral lesions. *Clin Orthop Relat Res*. 2018;476(10):2101-2104.
12. Kim HJ, Cho J, Lee S. Talonavicular joint mobilization and foot core strengthening in patellofemoral pain syndrome: a single-blind, three-armed randomized controlled trial. *BMC Musculoskelet Disord*. 2022;23(1):150. doi:10.1186/s12891-022-05099-x
13. Wheatley M, Rainbow MJ, Clouthier AL. Patellofemoral mechanics: a review of pathomechanics and research approaches. *Curr Rev Musculoskelet Med*. 2020;13(3):326-337.
14. Reider B, Marshall JL, Koslin B. The anterior aspect of the knee joint an anatomic study. *J Bone Joint Surg*. 1981;63(3):351-356.
15. Atbaşı Z, Parlak A, Aytekin A, et al. Genç erkek erişkinlerde ön diz ağrısının kondromalezi patella Q açısı ve patella tipleri ile ilişkisi. *Gülhane Tıp Derg*. 2013;55(2):89-93. doi:10.5455/gulhane.39853
16. Kaplan T, Başar H, İnanmaz ME. Sakarya ilindeki erişkinlerde patella tiplerinin dağılımı. *Sakarya Med J*. 2014;4(3):125-128. doi:10.5505/sakaryamj
17. Demirağ B, Kaplan T, Köseoğlu E. Türk toplumundaki erişkinlerde patella tiplerinin dağılımı. *Uludağ Üni Tıp Fak Derg*. 2004;30(2):71-74.
18. Gudas R, Šiupšinskas L, Gudaitė A, et al. The patello-femoral joint degeneration and the shape of the patella in the population needing an arthroscopic procedure. *Medicina*. 2018;54(2):21.
19. Rahman S, Ahmed Shokri A, Ahmad MR, et al. Intraoperative patella dimension measurement in Asian female patients and its relevance in patellar resurfacing in TKA. *Advances Orthop*. 2020;4539792. doi:doi.org/10.1155/2020/4539792
20. Demir M, Şahan MH. Evaluation of the relationship between trochlear and patellar morphology and patellar chondromalacia with magnetic resonance imaging. *Acta Orthop Belg*. 2023;89(3):409-416. doi:10.52628/89.3.11782
21. Mehl J, Feucht MJ, Bode G, et al. Association between patellar cartilage defects and patellofemoral geometry: a matched-pair MRI comparison of patients with and without isolated patellar cartilage defects. *Knee Surg Sports Traumatol Arthrosc*. 2016;24(3):838-846.
22. Sirik M, Uludag A. Assessment of the relationship between patellar volume and chondromalacia patellae using knee magnetic resonance imaging. *North Clin Istanbul*. 2019;7(3):280-283. doi:10.14744/nci.2019.65882
23. Fithian DC, Paxton EW, Stone ML, et al. Epidemiology and natural history of acute patellar dislocation. *Am J Sports Med*. 2004;32(5):1114-1121.
24. Dai Y, Yin H, Xu C, et al. Association of patellofemoral morphology and alignment with the radiographic severity of patellofemoral osteoarthritis. *J Orthop Surg Res*. 2021;16(1):548. doi.org/10.1186/s13018-021-02681-2